



# Technique Tips – The importance of a bitewing radiograph in the endodontic assessment of posterior teeth

## Assessment

A thorough clinical and radiographic assessment of a posterior tooth is essential prior to embarking on endodontic treatment. This is especially important when the tooth is restored with a large restoration, which is commonly the case. It is important that the restorability of the tooth is assessed. Assessment of the amount and quality of remaining tooth tissue from both direct examination and tactile feedback may be of limited value. Deep recurrent disease will often mean that a posterior tooth is not predictably restorable post endodontic treatment, without crown lengthening.

It is essential that every patient is made fully aware of the long-term challenges facing the restoration of broken down posterior teeth, which require endodontic treatment. This allows them to choose and consent to treatment in a fully informed manner. It also allows a comparative discussion with the dentist of other potential treatment options, including extraction and prosthetic replacement, ie with an implant. Part of this discussion might also involve the comparison of fees and the long term value for money of each option.

## A bitewing radiograph

It has been frequently reported that an optimally root-treated tooth without a good coronal seal has a greater risk of failure.<sup>1</sup> For most endodontically treated posterior teeth, this should be in the form of an indirect cuspal coverage restoration.<sup>2</sup> Deep proximal margins, however, mean that it may be difficult to prepare, record a good impression, and cement an indirect cuspal coverage restoration predictably.

Thus it is imperative to assess the quality and quantity of remaining natural tooth structure pre-operatively accurately; particularly the depth and location of the proximal box(es) to the alveolar bone height. A periapical radiograph is the most commonly used pre-operative image used to assess posterior teeth prior to endodontic

treatment. This often suffices for anterior teeth (particularly if a small film is used). There is an erroneous assumption that a long cone periapical radiograph (LCPA) provides a parallel image of the tooth. This is rarely the case for posterior teeth because of anatomical restrictions. The floor of the mouth and the palate mean that, for the majority of patients, the image, whilst perpendicular to the beam, is not parallel to the tooth. This has the effect of distorting the anatomy of the tooth and supporting structures, especially in the maxilla, which is less forgiving than the lingual sulcus (Figures 1 and 2).

Figure 1 shows there is little healthy tooth structure remaining on the distal aspect of the UL4, and a poorly adapted restoration on the mesial aspect of the UL6 appears to be encroaching on the biologic width. Using this radiograph alone, the authors would envisage that both teeth would be difficult to restore. However, Figure 3 demonstrates a very different picture from Figure 1. This is due to the limited lingual/palatal overlap of a bitewing, allowing a parallel image perpendicular to the UL4 to be recorded. This allows a more representative image to be recorded of the crown of the UL6 and thus a more accurate pre-treatment assessment of the amount of remaining tooth

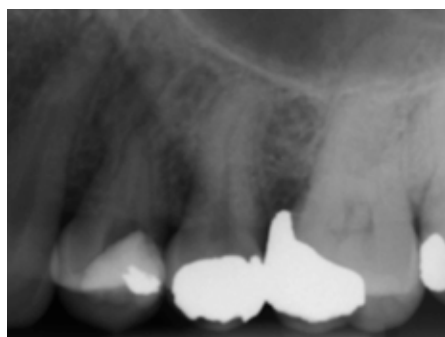tissue above the alveolar crest level.

In Figure 3, note that there now appears to be sufficient tooth structure remaining on the proximal aspects of both the UL4 and UL6, which should allow predictable restorations to be placed. In addition, there is an open contact visible between the restorations of the UL5 and UL6. Finally, the access cavity for the UL4 appears to be too large in a mesio-distal dimension, with a thin distal wall of tooth remaining and failure to unroof the pulp chamber. The endodontist should diligently avoid removal of more distal tooth tissue but rather should focus on deepening the centre of the access cavity by 1 mm.

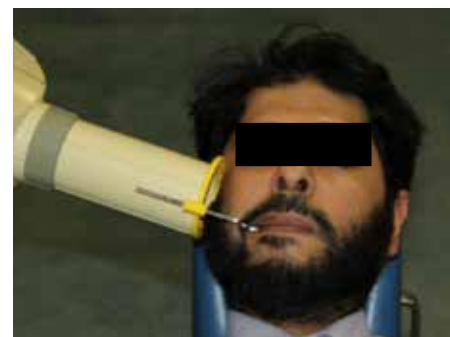Figure 2 demonstrates the usual angulation of a paralleling device and X-ray tube when taking a lower cone periapical radiograph in the upper right quadrant. Figure 4 demonstrates a more parallel angle allowable with a bitewing view of the same area, for the reasons discussed above.

It is also acknowledged that it may be difficult to achieve a true paralleling technique, because it relies on achieving:

- The tooth and film to be parallel to each other;
- The radiographic beam to be at 90 degrees to both the tooth and film.

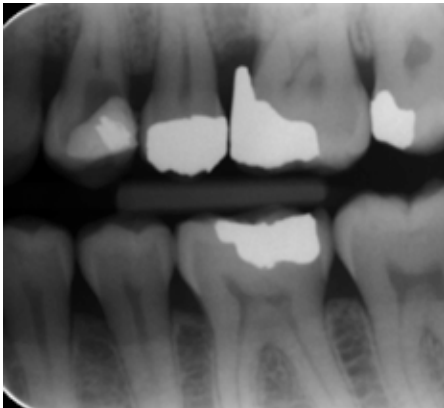


**Figure 1.** A long cone periapical radiograph used to assess the UL4 prior to endodontic treatment and localized periodontal pocketing around the mesial aspect of the UL6.



**Figure 2.** A photograph demonstrating the angulation obtained when taking a long cone periapical radiograph of a patient's upper right first molar tooth.

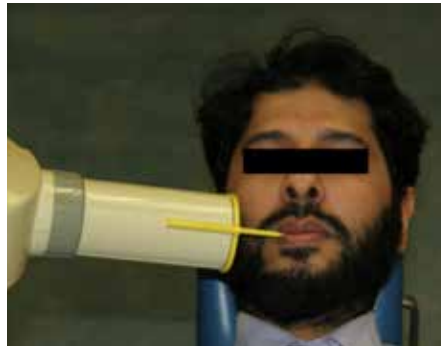**Arijit Ray-Chaudhuri**, BDS, MFDS RCS(Ed), MJDF RCS(Eng), LLM AHEA, FDS(RestDent) RCS(Eng), Consultant in Restorative Dentistry, Brighton and Sussex University Hospitals, Eastern Road, Brighton, East Sussex BN2 5BE, **Shabana Buth**, BDS(Hons), MFDS RCS(Ed), Career Development Post in Restorative Dentistry, Maxillo-Facial Unit, St George's Hospital, London, SW17 0QT and **Peter Briggs**, BDS, MSc, MRD FDS RCS(Eng), Consultant in Restorative and Implant Dentistry, Maxillo-Facial Unit, St George's Hospital, London, SW17 0QT.



**Figure 3.** A bitewing radiograph illustrates a different picture from Figure 1.

Therefore, there can always be a risk of deviation from the ideal technique, which can result in elongation or foreshortening of the roots. This is one of the major drawbacks of two-dimensional images.

When such an image is used to help assess the status of a heavily restored posterior tooth, it is likely to have the



**Figure 4.** A photograph demonstrating a more horizontal beam angulation obtained when taking a bitewing radiograph for the upper right first molar tooth.

following associated limitations:

- It can disguise any marginal defect and/or caries due to superimposition of the radio-opaque restorative material;
- It can distort the relationship between the bottom of a proximal box and the crest of the alveolar bone, making them appear closer (ie the box at alveolar bone level) and thus much

more difficult to restore;

- Distortion of the relationship between the occlusal table and the roof of the pulp chamber, which is essential to measure prior to accessing the tooth.

For these reasons, the authors recommend that a bitewing radiograph is taken in addition to a long cone periapical radiograph as it is a useful adjunct when paralleling periapical radiography proves difficult. This provides for a perpendicular image of the crown of the tooth and thus a more accurate assessment of the tooth prior to endodontic treatment.

## References

1. Ng YL, Mann V, Gulabivala K. A prospective study of the factors affecting outcomes of nonsurgical root canal treatment: part 1: periapical health. *Int Endod J* 2011; **44**(7): 583–609.
2. Aquilino SA, Caplan DJ. Relationship between crown placement and the survival of endodontically treated teeth. *J Prosthet Dent* 2002; **87**(3): 256–263.



## Introducing the 3i T3 IMPLANT™

The 3i T3™ Implant\* is designed to deliver aesthetic results through tissue preservation.



### PRESERVATION BY DESIGN™

- Contemporary hybrid surface design with multi-level topography; media-blasted on the threaded region and dual-acid etched on the collar region
- Optimized aesthetics with as little as 0.37mm of bone recession<sup>1</sup>
- Higher seal strength as compared to the competitive average<sup>2,3</sup>

Seal integrity test was performed by BIOMET 3i on December 2011. Testing was done under testing standard ISO 14801. Five (5) BIOMET 3i PREVAIL™ Implant Systems and five (5) of three (3) competitors' implant systems were tested. Bench test results are not necessarily indicative of clinical performance.

Please contact your local BIOMET 3i Sales Representative or visit us online at [www.biomet3i.com](http://www.biomet3i.com) to learn more.

**BIOMET 3i**  
PROVIDING SOLUTIONS – ONE PATIENT AT A TIME™

\*The 3i T3 Implant is not yet available for sale in the U.S.

1. Ostman PO, Wennerberg A, Albrektsson T. Immediate Occlusal Loading Of NanoTite Prevail Implants: A Prospective 1-Year Clinical And Radiographic Study. *Clin Implant Dent Relat Res*. 2010 Mar;12(1):39-47.  
2. Lazarsa R. Dental Implant System Design and the Potential Impact on Long-Term Aesthetics: A Review of the 3i T3™ Tapered Implant. ART1193EU 3i T3 White Paper. BIOMET 3i, Palm Beach Gardens, Florida, USA.  
3. Sultin Z, Tawse R, Cruz J. A Novel Method for Assessing Implant-Abutment Connection Seal Robustness. BIOMET 3i, Palm Beach Gardens, Florida, USA. Poster Presentation, Academy of Osseointegration, 27th Annual Meeting, March 2012;Phoenix, AZ. [http://biomet3i.com/Pdf/Posters/Poster\\_Seal%20Study\\_25\\_AO2012\\_nok%20logo.pdf](http://biomet3i.com/Pdf/Posters/Poster_Seal%20Study_25_AO2012_nok%20logo.pdf). Testing done by BIOMET 3i, Palm Beach Gardens, FL. n = 20.

\*Aforementioned have financial relationships with BIOMET 3i LLC resulting from speaking engagements, consulting engagements and other retained services. PREVAIL is a registered trademark of BIOMET 3i LLC. 3i T3, 3i T3 Implant design, Preservation By Design and Providing Solutions - One Patient At A Time are trademarks of BIOMET 3i LLC. ©2012 BIOMET 3i LLC.