



Peter Briggs

Arijit Ray-Chaudhuri and Kewal Shah

Avoiding and Managing the Failure of Conventional Crowns and Bridges

Abstract: The replacement of crowns and bridges is a common procedure for many dental practitioners. When correctly planned and executed, fixed prostheses will provide predictable function, aesthetics and value for money. However, when done poorly, they are more likely to fail prematurely and lead to irreversible damage to the teeth and supporting structures beneath. Sound diagnosis, assessment and technical skills are essential when dealing with failed or failing fixed restorations. These skills are essential for the 21st century dentist. This paper, with treated clinical examples, illustrates the areas of technical skill and clinical decisions needed for this type of work. It also provides advice on how the risk of premature failure can, in general, be further reduced. The article also confirms the very real risk in the UK of dento-legal problems when patients experience unexpected problems with their crowns and bridges.

Clinical Relevance: This paper outlines clinical implications of failed fixed prosthodontics to the dental surgeon. It also discusses factors that we can all use to predict and reduce the risk of premature restoration failure. Restoration design, clinical execution and patient factors are the most frequent reasons for premature problems. It is worth remembering (and informing patients) that the health of the underlying supporting dental tissue is often irreversibly compromised at the time of fixed restoration failure.

Dent Update 2012; 39: 78–84

The provision of conventional crowns and bridges is a common procedure for most general and specialist dental practitioners. It is estimated that more than one million crowns are placed per year under the NHS General

Dental Services (GDS) in England and Wales contract with an unknown number placed independently of this.¹ This represents a yearly spend of £117.5 million under the GDS contract alone in the year ending March 2005. It is likely that the total number of crowns placed (NHS, insurance and self-funded) is double that figure.

All qualified dentists will have encountered the failure of crowns and bridges (Figure 1). The most recent Adult Dental Survey² confirmed that 37% of adults have one crown or more (mean = 3) and 7% of adults have a bridge (3% aged 16–44 years and 14% aged 55–74 years). Unfortunately, the number of resin-bonded bridges still remains disappointingly low.³ Bartlett and co-workers have previously commented that practitioners are more likely to prescribe conventional bridges than adhesive alternatives.⁴

If conventional crowns and bridges are prescribed and maintained well they are likely to provide good clinical service and value for money. However, unless the restorations

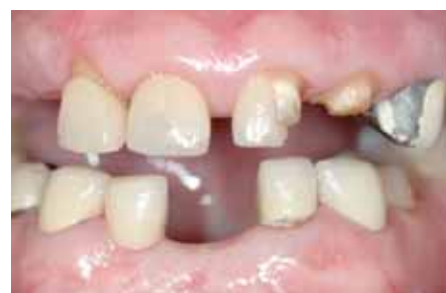

Figure 1. A patient with likely parafunction showing evidence of failure of both adhesive ceramic and conventional fixed restorations.

outlive the patient, they will eventually fail. The commonest cause of crown and bridge failure is caries^{5–8} (Figure 2). Many restorations will also fail as a result of de-cementation, or partial de-cementation in the case of bridges. For many bridge failures it is difficult to know whether de-cementation of an abutment preceded the caries or not. The authors consider that partial de-cementation and the

Peter Briggs, BDS(Hons), MSc, MRD, FDS RCS(Eng), Consultant in Restorative and Implant Dentistry, Maxillofacial Unit, St George's Hospital, London, SW17 0QT, Specialist Practitioner, Hodson House Specialist Referral Practice, Farningham, Kent DA4 0DH and BSSPD council member, **Arijit Ray-Chaudhuri**, BDS, MFDS RCS(Ed), MJDF RCS(Eng), LLM, Specialist Registrar in Restorative Dentistry, St George's Hospital, London, SW17 0QT and King's College Dental Hospital, London, SE5 9RW and **Kewal Shah**, BDS MFDS RCS(Eng), Specialty Dentist in Restorative Dentistry, St George's Hospital, London, SW17 0QT.

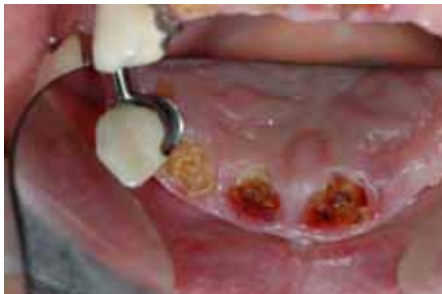

Figure 2. Gross secondary caries evident after removal of conventional crowns at UR1, UR2 and UL1. The patient will need a different restorative strategy to restore these teeth successfully.

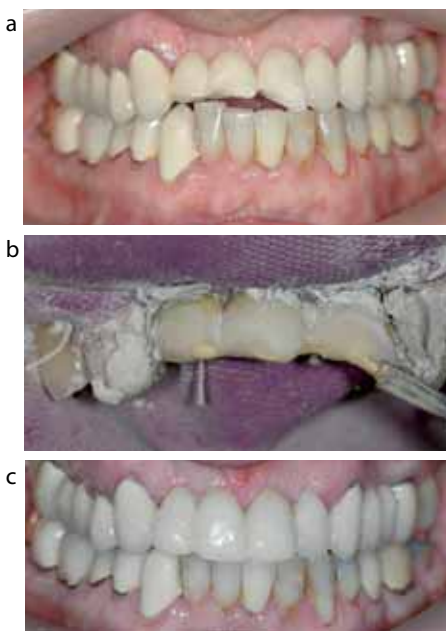


Figure 3. (a) Case 1: A frontal view of the patient described in Case 1 which illustrates fracturing of the veneering ceramic of UR1, UR2 and UL1. (b) Application of Sinfony™ Opaquer (3M ESPE) to the metal sub-structure of the bridge after intra-oral sandblasting. (c) Post-operative review of direct Gradia composite (GC) to mask the fractured ceramic.

breaking of the retainer seal is a common cause of catastrophic caries beneath bridges.

Pulpal and endodontic problems beneath otherwise well-functioning crowns and bridges are common.^{6,9-13} This means that dentists will often be required to undertake endodontic access through existing crowns or bridges or after they have been removed.

Tan *et al* found mechanical fracture to affect 3.2% of their reviewed fixed prostheses.⁹ It must also not be forgotten that some patients are unhappy with the

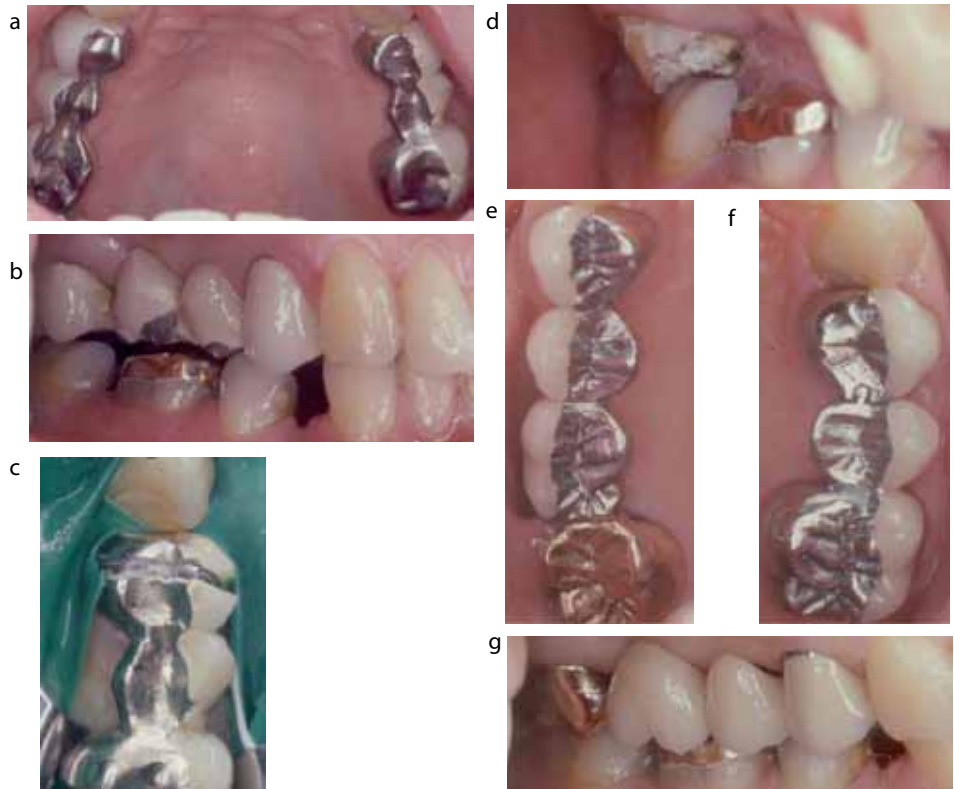


Figure 4. (a) Case 2: Maxillary occlusal view. The 3-unit fixed-fixed conventional porcelain fused to the metal bridge in the upper left quadrant replaced UL5 with a fracture of the ceramic on the pontic. The 4-unit fixed-fixed conventional bridge of the upper right quadrant replaced missing UR56. The right bridge displayed ceramic fracture on the labial aspects of the UR56 pontics. (b) Buccal aspects of the UR56

pontics. Existing ceramic fracture likely to reflect parafunction and inadequate metal support. (c) Clinical view of the bridge of the upper left quadrant after sectioning and prior to removal and investigation of UL46. Occlusal and palatal sectioning of retainers was achieved with a diamond bur for the porcelain and a new fluted tungsten carbide bur for the metal. The authors never recommend 'tapping off' conventional bridges as this is likely to lead to significant irreversible damage to the teeth and cores beneath. (d) The bridge in the upper right quadrant has been removed but occlusal contact between the UR7 and LR7 remains. The problem was resolved by further occlusal adjustment of UR7 and prescription of metal for the occlusal aspect of the future retainer (gold crown with pre-ceramic solder to UR6 pontic). Note some over-eruption associated with the LR6. (e) The same patient as above after cementation of the new posterior bridge in the upper right quadrant. Note that the bridge has been re-designed to incorporate a full veneer precious metal crown which has been soldered to the PFM elements of the bridge. This design allowed less tooth reduction on occlusal and buccal aspect UR7. Current evidence confirms that tooth preparation for posterior PFM accounts for approximately 76% of the coronal tooth structure.²⁶ (f) Cementation of the replacement bridge in the upper left quadrant. Note that the bridge has been re-designed to incorporate a movable joint between the pontic and the mesial abutment. The authors recommend an F/M joint where there is a significant difference in the likely retention offered by the major and minor abutments. The female slot should be placed within the distal aspect of the minor retainer and the male portion integral to the mesial aspect of the pontic. Metal ICP stops on metal surfaces of bridges and buccal ceramic are appropriately supported by underlying metal. (g) Buccal view after cementation of the bridge in the upper right quadrant. Note that the patient agreed to have a metal margin at the collar of the UR5 retainer (favourable lip line) which allowed the clinician to remove less tooth tissue in the cervical area. Metal collars on PFM crowns/retainers outside the aesthetic zone are acceptable to all but the most aesthetically aware patients.

final aesthetic result of their crowns and bridges.^{11,14-16}

Poor patient selection together with the sub-optimal clinical execution of tooth core build-up, tooth preparation(s), impression-

taking, jaw registration and cementation will increase the risk of early restoration failure. Unfortunately, the long-term prognosis of natural teeth beneath failed restorations will be detrimentally affected by these clinical

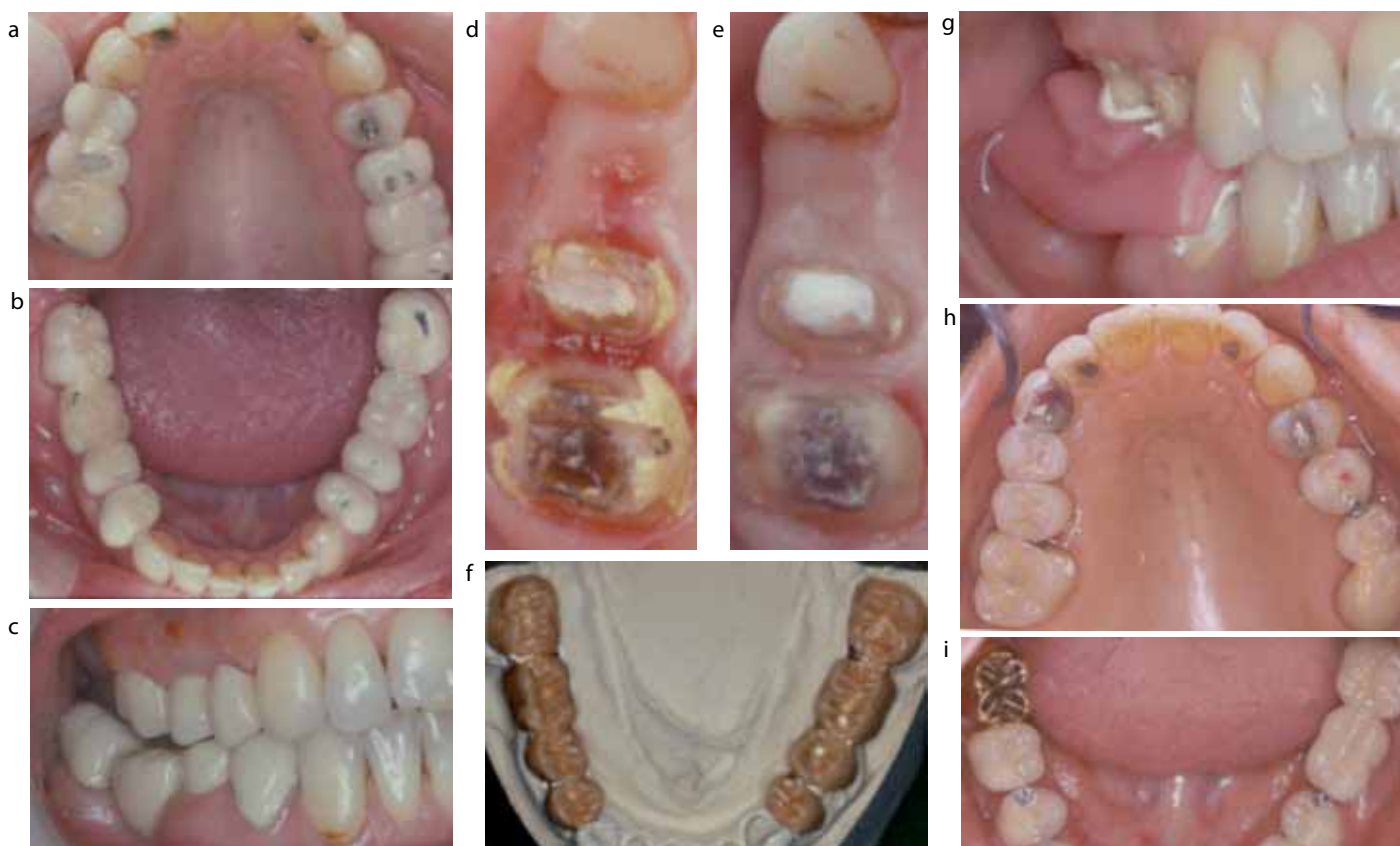

Figure 5. (a) Case 3: Upper occlusal view showing two posterior PFM bridges in the upper arch. (b) Lower occlusal view – the lower left quadrant restored with a 3-unit fixed-fixed conventional bridge. The lower right quadrant was restored with a 4-unit conventional bridge. (c) A right buccal view illustrating a lack of occlusion and posterior function of the upper and lower PFM conventional bridges on the right-hand side. The patient has an endodontic sinus from the failed RCT of the UR5. There was arrested bucco-cervical caries on the LR3 and areas of localized plaque-induced gingivitis. (d) Occlusal view after removal of the bridge in the upper right quadrant to allow investigation of UR56. Note gingival inflammation around the UR56 and the lack of occlusal height with UR5. (e) Occlusal view after crown lengthening surgery and temporization of UR56. The UR5 also required apical surgery. Note that the UR3 is unrestored and therefore amenable to act as an abutment tooth for a predictable adhesive bridge. (f) Full contour diagnostic wax-up created prior to removal of bridges. Also used to construct indirect provisional restorations. (g) Right buccal view after investigation and restoration of the abutment teeth. The patient had temporary bridges *in situ* for three months to make the best assessment of the modified occlusal scheme. Definitive bridges were placed on the right side first. An interocclusal record was taken with Micro-Beauty Wax (Moyco, USA) which was only supported by the prepared posterior teeth on the right side. The anterior natural teeth and the left provisional bridges stabilized other areas of the occlusion during the right jaw registration, which was further refined by reline with TempBond (Kerr Dental, UK). (h) Upper occlusal view of the fit and adjustment of the restorations in the URQ. Note the distal cantilever adhesive bridge replacing the UR4. The occlusal aspects of UR45 will be polished once the occlusion is appropriate. The UR4 has been restored with a distal adhesive bridge from UR3 which allows the root-filled UR5 to be restored as an individual crown. Upper left quadrant has been redesigned with fixed-movable restoration. The ‘bottomed-out’ female portion of the joint is placed within the distal aspect of the minor retainer (UL5) and the male component is part of the anterior aspect of the pontic. (i) Lower occlusal view after final cementation of the definitive bridges. (j) Anterior view after review of replacement crowns and bridges. Note that the sinus has healed at UR5. Pre-operative discussions confirmed that lip line allowed patient to accept metal collars.

General Dental Council (GDC). The commonest area of complaint was treatment related to crowns (196) followed by bridges (116).¹⁶

This article highlights the important areas of clinical risk and how they can be avoided at the time of initial restoration prescription. With the aid of clinical examples, the article will also offer technical and clinical advice that can be used at the time of failure.

Clinical examples of failed conventional fixed restorations

Case 1 (Figure 3 a–c)

This 67-year-old male patient

shortcomings.

Dentists working in the UK are now among the most likely in the world to be

exposed to dento-legal problems. Between 2009/10 there were 1180 complaints received by the Dental Complaints Service at the

presented with a fractured 10 unit PFM bridge extending from the UR4 to the UL6. The fracture was limited to the veneering ceramic of UR1, UR2 and UL1. The damage was caused by a fall and there was no evidence of damage to the rest of the restoration. The abutments were healthy with no evidence of de-cementation. The patient's major concern was the aesthetic impact of the damage. Following discussions with the patient, which included an explanation of all treatment options, it was decided to accept the existing fixed restoration and attempt a repair of the fractured ceramic with direct resin. The patient realized that, if this treatment proved unsuccessful, the maxillary anterior bridge would need to be removed to allow careful investigation of the abutments to plan for future treatment.

Case 2 (Figure 4 a–g)

A 40-year-old female patient presented with two maxillary posterior PFM bridges that displayed ceramic fracture. She was unhappy with the resultant cosmetic impairment and the visible dark areas of the underlying metal. The bridges had been *in situ* for approximately 10 years and had always been slightly uncomfortable since cementation. She gave a history of possible parafunction. There was no evidence of de-cementation or pathology associated with the four abutment teeth. The thought processes of the treating clinician included:

- Why has the ceramic fractured and what am I going to do differently to ensure that a similar problem does not happen with a new restoration?
- How am I going to remove the restorations safely and ensure that I can make and fit good quality provisional restorations?
- What future designs will I use for the replacement bridges and will the patient accept cervical metal collars and metal occlusal surfaces?

Case 3 (Figure 5 a–j)

This female patient was referred with pain and infection under her conventional bridge in the upper right quadrant and an inability to make occlusal contact and function with her posterior bridges. The patient was a medically well 50-year-old. Figures 5 (a–j) outline the practical steps of investigating the status of underlying tooth tissues and improving

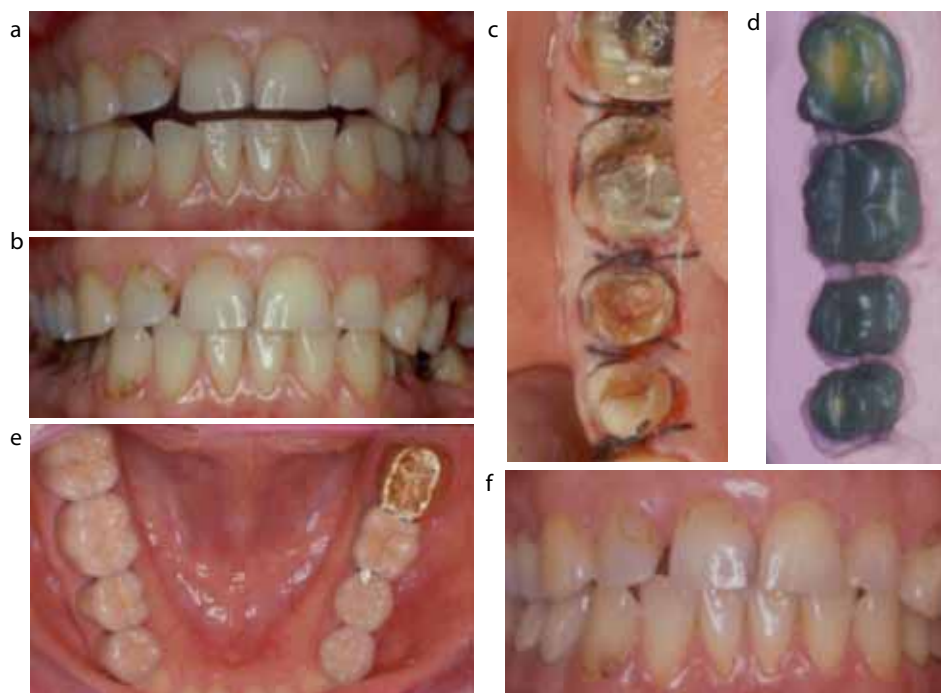

Figure 6. (a) Case 4: Anterior view – the patient had a partial coverage splint that extended from UR2 to UL2 and was worn constantly. The patient presented with an anterior open bite and contact on her posterior teeth and temporary posterior restorations only in her inter-cuspal position (ICP). Thin unreliable provisional restorations were *in situ* on the LR4567 and LL457. (b) The lower posterior temporary restorations were removed to allow contact between the anterior teeth at a reduced vertical dimension. At this vertical dimension the patient was comfortable and able to display lateral and protrusive guidance on the natural anterior teeth. It was also felt that this relationship would aid the fabrication of the posterior restorations. (c) Occlusal view showing the LR4567 after crown lengthening surgery which was needed to improve their clinical crown height. Note that the root-filling of LR5 was exposed to oral fluids. (d) 'Cut-back' wax-ups for the metal substructures of new PFMs for LR4567. A pink putty matrix was taken of the full contour wax-ups. This ensures optimum design, thickness of metal and support of future ceramic. (e) Lower occlusal view after cementation of definitive restorations. The patient requested tooth-coloured occlusal surfaces where possible. Individual PFM crowns were placed on LL4 and LR4567. The bridge in the lower left quadrant was redesigned to incorporate a movable joint into the posterior part of the LL5 with PFM full coverage minor retainer and a pre-ceramic soldered full veneer precious metal crown as the distal major retainer. (f) Anterior view at 24 months after placement of her definitive mandibular restorations. The patient was able to contact her anterior and posterior teeth in her ICP.

(with the aid of crown lengthening surgery and endodontic revision) the quality of the support for replacement restorations. The success of this case relied on the correct planning and execution of static jaw registration.

Case 4 (Figure 6 a–f)

This case represents problems that can flow from over zealous technical treatment of temporo-mandibular dysfunction (TMD). The questions asked by the treating clinician included:

- Is the TMD under control?

- At what vertical dimension will I be able to get anterior tooth contact and how much occlusal space will there be for the posterior fixed restorations?
- Will there be enough remaining tooth tissue to provide predictable fixed mandibular restorations?
- I will be short of occlusal height at LL7 – can I get the patient to accept metal occlusal surface on this tooth?
- Does the patient realize the difficulty of her treatment and the time and effort that will be involved in improving her situation?
- Is the patient happy to wear a splint after completion of treatment?

Risk factors associated with failure of crowns and bridges

Patient issues

Obtaining a thorough patient history is always essential prior to the prescription of *de novo* or replacement conventional fixed prosthesis. The history should focus on the 'patient-driver(s)' for the crowns/bridges, as opposed to accepting the space or using an adhesive bridge, denture or implant(s). The authors ask patients 'open' questions designed to encourage a two-way discussion. Examples of such questions include:

- 'How much does the space worry you?'
- 'What are the main reasons for you wanting fixed crowns or bridges?'
- 'Would you consider wearing a denture and, if not, why not?'
- 'How long are you expecting these new restorations to last?'
- 'Unfortunately your bridge has failed and the supporting teeth are very compromised. How do you feel about the support teeth being restored with single crowns and either accepting your space or restoring it with a denture or implant?'
- 'What aesthetic problems do you have with your existing teeth? How do you think that crown and bridge work can help?'

If a patient is wearing a denture it is important to confirm whether it has a flange and, if so, whether it is essential for the maintenance of facial/lip support. A fixed conventional or implant restoration is unlikely to be a good restorative option where the patient needs additional facial support following post-extraction alveolar resorption. In such a circumstance, a flangeless denture try-in is the only way to confirm the feasibility of using a fixed restoration.

It is essential that the patient knows, at the outset, that pulpal death is a potential complication of crowns and bridges. They should also understand that this risk is greater with bridge abutments and for teeth with significant restorations *in situ*.¹⁷

Patients should also have an understanding of the following:

- The number of appointments;
- The likely period of temporization;
- The likely biological damage delivered to the prepared teeth; and
- The probable survival time of the planned restoration(s).

The authors find that a fully-informed patient will always cope better with

'pre-warned' complications compared to unpredicted problems. Any explanation of the latter will always sound like an excuse for poor treatment to the patient.

When dealing with failed conventional indirect restorations the patient should always be advised, at the outset, that an accurate 'financial quote' may not be possible until a thorough clinical investigation has been undertaken. The authors would also suggest that all patients accept and understand that the initial phase of dealing with failed restorations is an investigation of the supporting teeth. This will involve initial removal of the failed restoration(s), assessment of the quality and quantity of remaining tooth tissue (together with an indication for endodontic treatment or crown lengthening) and a suggestion of appropriate long-term treatment options.

At the time of failure a patient should be aware of what they 'bring-to-the-table' in terms of the risk of future replacement restorations. They should be aware of the importance of home plaque control, future hygiene recall, smoking cessation, control of dietary intake of sugars and the use of fluoride prevention.

The authors' advice is that it is always best to refuse treatment at the onset if it is felt that it is not in the patient's best interest. Early pre-treatment referral to an appropriate hospital or practice-based specialist will add further reassurance where there are difficult issues.

Oral hygiene

One of the most important factors that affects the likely performance of replacement fixed restorations is the patient's ability to clean and maintain his/her dentition. Patients should understand that plaque control around fixed restorations will be more difficult than for natural teeth. Unwillingness or an inability to affect appropriate hygiene will not bode well for any replacement crowns and bridges (Figures 3–5). Patients should be encouraged to use interdental and 'beneath-the-pontic' cleaning aids on a daily basis.

If a patient is susceptible to caries, then they should supplement their cleaning regime with a fluoride supplement and a thorough dietary analysis should be undertaken and recorded prior to any treatment.

Smoking

Although smoking is not a contraindication to the repair or replacement of failing crowns and bridges, the patient should be aware that the habit will undermine the survival time of any replacement restorations. All patients who smoke should be offered smoking cessation advice¹⁸ and enhanced prevention measures (eg fluoride supplements and more regular hygiene recall).

Crown and bridge factors

Design

Gold crowns have been shown to survive better than porcelain fused to metal crowns. Single unit restorations have also been shown to survive better, and damage fewer teeth on failure, when compared to fixed bridges. The ceramic must always be used appropriately supported by any underlying metal.

Cantilever bridges

Traditional wisdom suggested that pontics should have support by abutments on each side of the span. This view is no longer held, as conventional single unit cantilever bridges can perform well. Ideally, the abutment tooth should be substantial in comparison to the pontic space, eg a first molar supporting a missing second premolar or a canine replacing a missing lateral incisor. Conventional double and distal cantilever bridges should be used with more caution as both designs are associated with higher failure rates than single mesial cantilevers and teeth with a distal abutment.¹⁹

Position of proposed bridge

More conventional bridges are placed, and therefore likely to fail, in the anterior zone of the maxilla. Both anterior and posterior bound conventional bridges show predictable long-term survival (estimated at approximately 90% at 10 years).²⁰ Unfortunately, bridges that combine anterior and posterior teeth (ie extend in front of and behind a canine) tend to have a less good outlook. Such bridges are often used to replace missing canines.

Number of units within bridge

Unfortunately, some dentists cannot resist the inclusion of multiple (more than two) abutments within the bridge design.

Unfortunately this locks-in sound teeth to other compromised abutments. The survival of any bridge will always be dictated by the most compromised tooth. In general, if the two teeth next to a pontic space are unable to support a bridge predictably, then another restorative option should be considered.

In general, a bridge of more than four units is high risk.^{21,22}

Four missing incisors can be restored predictably with a six-unit conventional bridge, with full coverage crowns placed on the canine teeth. This may be acceptable as long as the patient has rejected a denture or implants/adhesive bridge following unbiased treatment planning discussions. Eventually such a bridge will fail, which will cause compromise to at least one of the supporting canines.

Design of retainer

The authors usually use full coverage crowns for anterior conventional bridges with no movable joints. For posterior teeth the prescription of choice would be both full and $\frac{3}{4}$ coverage retainers, as these demonstrate predictable survival as major retainers.²³ A $\frac{3}{4}$ crown or onlay can be used predictably as a posterior minor retainer. It should be appreciated that endodontically-treated teeth make poorer abutments than vital teeth and, when restored with a post, they are high risk beneath bridges. This is especially the case in cantilevered bridges and bridges with more than three units.^{24,25}

Material

Porcelain fused to metal crowns are the most common type of full coverage restoration prescribed in the GDS (approximately 80%), followed by full coverage metal crowns and all ceramic crowns. PFMs have been shown by Burke and Lucarotti¹ to have a lower 10-year survival than full metal crowns (48% vs 68%) used within the NHS GDS service. A common cause for re-intervention of PFM crowns and bridges is fracturing of the veneering ceramic, which is estimated to cause 2–3% of all failures.²⁵ With modern adhesive technology it is often possible to attempt repair with composite resin, although the long-term performance of such repairs is unknown.

Radiographic assessment

Bitewing radiographs are often

underused in the assessment and management of failing posterior crowns and bridges. They provide a near parallel image of the abutment teeth (unlike periapical radiographs that are often compromised by the anatomy of the floor of the mouth or palate). Bitewings are excellent for diagnosing recurrent caries, early bone loss (up to 5 mm) and assessing the amount of likely sound tooth tissue above the alveolar crest.

Conclusion

The cases used in this publication illustrate the challenges present when dealing with failing indirect restorations. Management should always include an initial investigation, which will then be followed by repair, removal with replacement, or use of a different form of restoration.

References

- Burke FJT, Lucarotti PSK. Ten-year outcome of crowns placed within the General Dental Services in England and Wales. *J Dentistry* 2009; **37**: 12–24.
- Adult Dental Health Survey 2009. Summary report and thematic series.
- Steele JG, Treasure E, Pitts NB. Total tooth loss in the United Kingdom in 1998 and implications for the future. *Br Dent J* 2000; **189**: 589–603.
- Bartlett D, Preiskel A, Shah P *et al*. An audit of prosthodontics undertaken in general dental practice in the South East of England. *Br Dent J* 2009; **207**: E17.
- Goodacre CJ, Bernal G, Rungcharassaeng K *et al*. Clinical complications in fixed prosthodontics. *J Prosthet Dent* 2003; **90**(1): 31–41.
- Holm C, Tidehaq P, Tillberg A *et al*. Longevity and quality of FPDs: a retrospective study of restorations 30, 20, and 10 years after insertion. *Int J Prosthodont* 2003; **16**: 283–289.
- Karlsson S. A clinical evaluation of fixed bridges, 10 years following insertion. *J Oral Rehabil* 1986; **13**: 423–432.
- Leempeol PJB, Eschen S, De Hann AFJ *et al*. An evaluation of crowns and bridges in a general dental practice. *J Oral Rehabil* 1985; **12**: 515–528.
- Tan K, Pjetursson B, Lang N *et al*. A systematic review of the survival and complication rates of fixed partial dentures (FPDs) after an observation period of at least 5 years III. Conventional FPDs. *Clin Oral Implants Res* 2004; **15**: 654–666.
- Clark-Holke D, Drake D, Walton R. Bacterial penetration through canals of endodontically treated teeth in the presence or absence of the smear layer. *J Dentistry* 2003; **31**: 275–281.
- Caplan DJ, Kolker J, Rivera EM *et al*. Relationship between number of proximal contacts and survival of root canal treated teeth. *Int Endodont J* 2002; **35**: 193–199.
- Chailertvanitkul P, Saunders WP, Saunders EM *et al*. An evaluation of microbial coronal leakage in the restored pulp chamber of root-canal treated multirooted teeth. *Int Endodont J* 1997; **30**: 318–322.
- Bergenholtz G, Nyman S. Endodontic complications following periodontal and prosthetic treatment of patients with advanced periodontal disease. *J Periodont* 1984; **55**: 63–68.
- Walton TR. A 10-year longitudinal study of fixed prosthodontics: clinical characteristics and outcome of single-unit metal-ceramic crowns. *Int J Prosthodont* 1999; **12**: 519–526.
- Palmqvist S, Swartz B. Artificial crowns and fixed partial dentures 18 to 23 years after placement. *Int J Prosthodont* 1993; **6**: 279–285.
- Helping You Put Things Right*. Dental Complaints Service Annual review – 2009/10.
- Cheung GSP, Lai SCN, Ng RPY. Fate of vital pulps beneath a metal-ceramic crown or a bridge retainer. *Int Endodont J* 2005; **38**: 521–530.
- Watt RG, Daly B (Series Editor Kay EJ). Prevention. Part 1: Smoking cessation advice within the general dental practice. *Br Dent J* 2003; **194**: 665–668.
- Randow K, Glantz P, Zoger B. Technical failures and some related clinical complications in extensive fixed prosthodontics: an epidemiological study of long-term clinical quality. *Acta Odont Scand* 1986; **44**: 241–255.
- Scurria M, Bader JD, Shugars DA. Meta-analysis of fixed partial denture survival: prostheses and abutments. *J Prosthet Dent* 1998; **79**: 459–464.
- Reuter JE, Brose MO. Failures in full crown retained dental bridges. *Br Dent J* 1984; **157**: 61–63.
- Foster LV. The relationship between failure and design in conventional bridgework from general dental practice. *J Oral Rehabil* 1991; **18**: 491–495.
- Roberts DH. The failure of retainers in bridge prostheses. An analysis of 2,000 retainers. *Br Dent J* 1970; **128**: 117–124.
- De Backer H, Van Maele G, De Moor N *et al*. A 20-year retrospective survival study of fixed partial dentures. *Int J Prosthodont* 2006; **19**: 143–153.
- De Backer H, Van Maele G, De Moor N *et al*. Long-term survival of complete crowns, fixed dental prostheses, and cantilever fixed dental prostheses with posts and cores on root canal-treated teeth. *Int J Prosthodont* 2007; **20**: 229–234.
- Edelhoff D, Sorensen JA. Tooth structure removal associated with various preparation designs for anterior teeth. *J Prosthet Dent* 2002; **87**: 503–509.